

## Intravitreal Injections

An intravitreal (pronounced *in tra VIT re al*) injection is a procedure to place a medication directly into the space in the back of the eye called the vitreous cavity, which is filled with a jelly-like fluid called the vitreous humor gel. The procedure is usually performed by a trained retina specialist in the office setting.

### What are intravitreal injections used for?

Intravitreal injections are used to administer medications to treat a variety of retinal conditions. Age-related macular degeneration (AMD), diabetic retinopathy and retinal vein occlusion are the most common conditions treated with intravitreal **anti-VEGF drugs**. Intravitreal steroids are used in some eyes with diabetic retinopathy, retinal vein occlusion and uveitis. The anti-VEGF drugs and steroids help to reduce fluid leakage associated with these disorders. Antibiotic, anti fungal and antiviral drugs are also used to treat patients with infections in the eye such as **endophthalmitis** and retinitis. In some cases an injection is used to insert a small gas bubble to aid repair of a **retinal detachment**.

### What kind of drugs can be given by intravitreal injection?

- **anti-VEGF drugs**
- Steroids, which reduce inflammation
- Antibiotics, antiviral and antifungal medications

### The intravitreal injection procedure

Intravitreal injections are performed in the office, often with the patient reclined in a chair. First, the eye and eyelids are anesthetized using drops or gel so the injection doesn't hurt. Sometimes a small numbing injection may be given.

The eye and the eyelids are then cleaned, usually using povidone-iodine, a yellow solution which is very effective at killing bacteria that live around the eye. An **eyelid speculum** is often used to keep the eyelids open during the procedure. Once the eye is prepped for injection, you will be asked to look in a particular direction depending on the location of the injection while the medicine is injected through the pars plana (the white part of the eye) with a very small needle.

Typically, patients feel pressure, with little or no pain during the injection. After the injection, the speculum is removed and the eye is cleaned. The entire process takes about 10 to 15 minutes.

### Safety and results

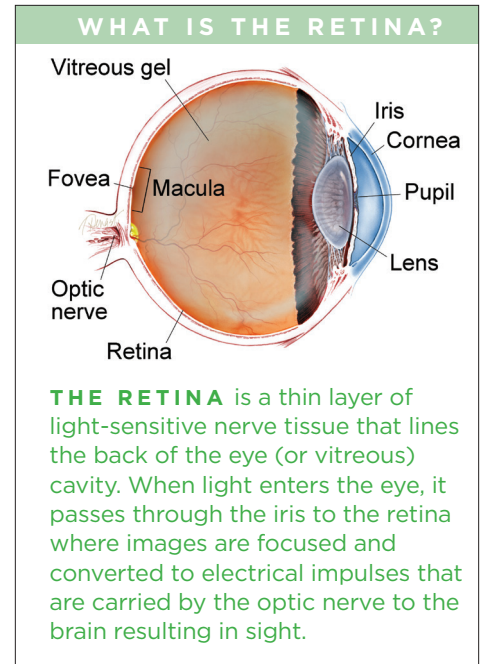
Severe complications are very rare with intravitreal injections. The major risks are:

- Infection in the eye or *endophthalmitis*
- Inflammation in the eye or *pseudoendophthalmitis* (a non-infectious, inflammatory reaction to some medications)
- Bleeding into the vitreous gel (vitreous hemorrhage)
- Retinal detachment

Sometimes there may be a small bleed or *subconjunctival hemorrhage* on the surface of the eye where the needle enters; this usually heals within a week.

Your retina specialist may check the intraocular pressure (IOP), that is, the pressure within the eye, following the injection. There is a temporary rise in

*continued next page*



## Intravitreal Injections *continued from previous page*

IOP that usually returns to baseline in a few minutes. The IOP may take longer to normalize in patients with glaucoma and needs to be monitored.

### What to expect after the injection

There are usually no restrictions following the injection apart from avoiding potential contamination of the eye on the day of the injection. However, you should contact your retina specialist if you experience signs and symptoms of complications, such as:

- Eye pain or discomfort
- Increased floaters after the first day
- Increased sensitivity to light
- Decreased vision

Sometimes after an intravitreal injection, you may get the feeling that “something is in your eye”—this can be a reaction to povidone-iodine, which is used to clean the eye before the injection. Artificial tears (preferably sterile single use droppers) can be used to help ease symptoms of dryness and surface irritation.

A follow-up visit with your retina specialist will be scheduled depending on the disease being treated, but is usually about 4 to 6 weeks after the injection.

### Repeated intravitreal injections

Intravitreal injections are an indispensable tool for the retina specialist to treat a variety of conditions. Their use has become much more common since the introduction of anti-VEGF medications in 2006. Intravitreal injections often need to be repeated in chronic conditions such as AMD, diabetic macular edema, and retinal vein occlusions, which require frequent office visits. Repeat injections are usually safely tolerated over several years. The need for a repeat injection is determined during the clinical examination, often with the use of diagnostic testing such as **optical coherence tomography (OCT)** and **fluorescein angiography (FA)**.

Research is underway that will hopefully provide longer-acting treatments in the near future.

### Clinical Terms *(appearing green within fact sheet text)*

**Anti-VEGF medications:** Elevated vascular endothelial growth factor (VEGF), a soluble factor that can be produced in eyes with poor circulation, can lead to swelling and the growth of abnormal new blood vessels in the eye. Leaky blood vessels cause swelling such as macular edema and are prone to bleeding, both of which cause decreased vision. Anti-VEGF drugs which inactivate VEGF have revolutionized treatment allowing retina specialists to reduce new blood vessel growth and swelling with periodic injections of anti-VEGF drugs including bevacizumab (Avastin®), ranibizumab (Lucentis®), and aflibercept (Eylea®).

**Endophthalmitis:** An infection inside the eye. It is characterized by decreased vision and sometimes severe pain and increased floaters. This can lead to severe vision loss if not treated promptly.

**Eyelid speculum:** Medical device used to keep the eyelid open during ocular procedures and surgeries. It typically has two blades that hold the upper and lower lid apart.

**Fluorescein angiography (FA):** An imaging technique where a yellow dye called *sodium fluorescein* is injected into a vein in the arm, allowing a special camera to record circulation in the retina and *choroid* in the back of the eye. This test can be very useful in diagnosing a number of retinal disorders.

**Optical coherence tomography (OCT):** A non-invasive imaging technique that uses light to create a 3-dimensional image of your eye for physician evaluation.

**Retinal detachment:** A condition where the retina separates from the back of the eye cavity. This may be caused by vitreous gel or fluid leaking through a retinal tear or hole and collecting under the retina causing it to separate from the tissue around it.

### THANK YOU TO THE RETINA HEALTH SERIES AUTHORS

Sophie J. Bakri, MD  
Audina Berrocal, MD  
Antonio Capone, Jr., MD  
Netan Choudhry, MD, FRCS-C  
Thomas Ciulla, MD, MBA  
Pravin U. Dugel, MD  
Geoffrey G. Emerson, MD, PhD  
Roger A. Goldberg, MD, MBA  
Darin R. Goldman, MD  
Dilraj S. Grewal, MD  
Larry Halperin, MD  
Vincent S. Hau, MD, PhD  
Suber S. Huang, MD, MBA  
Mark S. Humayun, MD, PhD  
Peter K. Kaiser, MD  
M. Ali Khan, MD  
Anat Loewenstein, MD  
Mathew J. MacCumber, MD, PhD  
Maya Maloney, MD  
Hossein Nazari, MD  
Oded Ohana, MD, MBA  
George Parlitsis, MD  
Jonathan L. Prenner, MD  
Gilad Rabina, MD  
Carl D. Regillo, MD, FACS  
Andrew P. Schachat, MD  
Michael Seider, MD  
Eduardo Uchiyama, MD  
Allen Z. Verne, MD  
Yoshihiro Yonekawa, MD

### EDITOR

John T. Thompson, MD

### MEDICAL ILLUSTRATOR

Tim Hengst